

## Diagnosis of a Space-Occupying Lesion of the Lung by Pulmonary Function Tests

Suzanne Redden MD, Deborah A Hunton RRT RPFT, and David A Kaminsky MD

### Case Presentation

A 13-year-old girl was referred to the pulmonary clinic by her pediatrician for a nonproductive cough and abnormal spirometry and chest radiograph. The patient had been well until 4 weeks earlier, when she developed an upper respiratory tract infection characterized by sinus congestion, sore throat, nonproductive cough, and low-grade fevers. Her symptoms all resolved after a few days except for the cough, which was persistent and raised concern about residual bronchial hyperresponsiveness, so spirometry with bronchodilator testing was conducted (Table 1 and Fig. 1).

**Question.** What do the spirometry and flow-volume loop show?

**Answer.** The spirometry reveals low forced vital capacity (FVC), low forced expiratory volume in the first second ( $FEV_1$ ), and low  $FEV_1/FVC$  ratio, but the flow-volume loop does not suggest expiratory air flow limitation. There is no significant improvement in air flow following treatment with inhaled bronchodilator. The discrepancy between the low  $FEV_1/FVC$  ratio and the normal shape of the latter portion of the expiratory loop is probably due to a low  $FEV_1$  having been produced because of a low peak flow caused by suboptimal technique or effort. Overall, the spirometry data are most consistent with a restrictive process, neuromuscular weakness, or suboptimal effort.

---

Suzanne Redden MD and David A Kaminsky MD are affiliated with the Department of Pulmonary Disease and Critical Care Medicine, Fletcher Allen Health Care, University of Vermont College of Medicine, Burlington, Vermont. Deborah A Hunton RRT RPFT is affiliated with the Respiratory Care Department, Fletcher Allen Health Care, Burlington, Vermont.

Correspondence: David A Kaminsky MD, Pulmonary Disease and Critical Care Medicine, Fletcher Allen Health Care, University of Vermont College of Medicine, Given C-317, Burlington VT 05405. E-mail: dkaminsk@zoo.uvm.edu.

**Question.** What pulmonary function test (PFT) should be ordered next?

**Answer.** The only way to definitively resolve whether the low FVC is from a restrictive process, as opposed to neuromuscular weakness or suboptimal effort, is to directly measure lung volumes. Lung volumes were measured with the helium dilution technique (Table 2).

**Question.** How do you interpret the lung volume data?

**Answer.** The lung volumes show a severely reduced total lung capacity (TLC) and functional residual capacity (FRC), with a reduced residual volume (RV) but elevated RV/TLC ratio. These results are consistent with restriction, with concomitant air trapping, or suboptimal effort. This pattern is also compatible with a pleural process, such as pleural effusion or pneumothorax. The vital capacity (VC) (slow) is approximately the same as that measured during spirometry (forced), indicating no substantial airway compression or collapse. The normal helium equilibration time suggests that if there is air trapping, it is in regions that are essentially not communicating with the airway tree, as opposed to being in areas with long time constants (ie, in areas with poor communication that simply take a longer time to receive the inert gas).

The patient denied any shortness of breath, wheezing, or chest discomfort. Her parents stated that she had been a healthy, full-term infant who had grown normally without any major illnesses. At school the patient had no difficulty keeping up with her classmates, and she enjoyed soccer and swimming.

On physical examination the patient appeared well, and her cough was substantially improved. Her vital signs were blood pressure 99/60 mm Hg, heart rate 96 beats/min, respiratory rate 16 breaths/min, temperature 37° C, and oxygen saturation (measured via pulse oximetry) 99% on room air. The trachea was slightly shifted to the right side, and heart sounds were also heard best toward the center of the chest. On the left side the chest was hyperresonant to percussion and breath sounds were completely absent. On

## DIAGNOSIS OF A SPACE-OCCUPYING LESION OF THE LUNG BY PULMONARY FUNCTION TESTS

Table 1. Spirometry Values Before and After Administration of Albuterol

	Value (% of Predicted)		% Change
	Before Albuterol	After Albuterol	
FVC (L)	1.65 (49)	1.61 (48)	-2
FEV <sub>1</sub> (L)	1.16 (35)	1.27 (38)	9
FEV <sub>1</sub> /FVC	0.70 (71)	0.78 (79)	11

FVC = forced vital capacity  
FEV<sub>1</sub> = forced expiratory volume in the first second

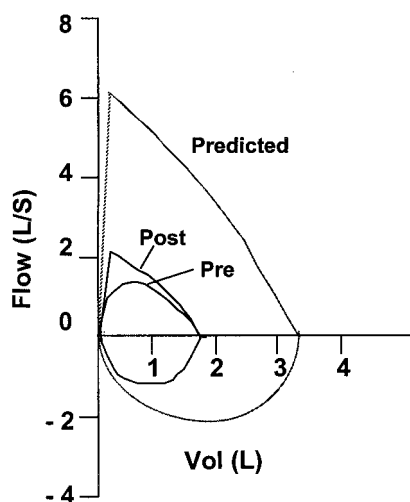


Fig. 1. Predicted flow-volume loop and loops obtained pre-bronchodilator and post-bronchodilator.

the right side percussion and breath sounds were normal. The rest of the exam was completely normal.

The PFT finding of apparent severe restriction was surprising because the patient had no signs of chest wall restriction on examination and no abnormal lung sounds on the right side to suggest interstitial fibrosis or a pleural process. Even though the physical findings suggested tension pneumothorax, that diagnosis was not compatible with the patient's stable clinical status.

**Question.** What other lung lesions could cause complete absence of breath sounds on one side of the chest in a young patient such as this?

**Answer.** The first entity to consider would be lung atelectasis from bronchial obstruction, but in this case atelectasis would lead to volume loss and shift of the trachea or heart toward the left, not toward the right. Any abnormality in lung development, leading to a nonfunctioning lung on the left, could also result in the above findings. Such abnormalities include congenital or acquired underdevelopment of one lung or congenital lobar emphysema.<sup>1</sup>

Table 2. Lung Volumes Obtained via Helium Dilution

	Value (% of Predicted)
TLC (L)	2.29 (50)
FRC (L)	1.12 (56)
RV (L)	0.76 (78)
RV/TLC	0.33 (156)
ERV (L)	0.36 (35)
IC (L)	1.17 (46)
VC (L)	1.54 (46)
Helium equilibration time (min)	2.13

TLC = total lung capacity  
FRC = functional residual capacity  
RV = residual volume  
ERV = expiratory reserve volume  
IC = inspiratory capacity  
VC = vital capacity

Finally, a space-occupying lesion could result in compression and nonfunctioning of the healthy adjacent lung, such as one might see with bronchogenic or pulmonary cysts, pulmonary sequestrations, or cystic adenomatoid malformations.<sup>1</sup>

**Question.** In addition to obtaining a chest radiograph, what other PFTs should be performed to further define the pulmonary process?

**Answer.** Lung volumes should be measured via body plethysmography to determine if there is a true restrictive process as opposed to a large region of noncommunicating gas. Table 3 shows the body plethysmography results.

**Question.** How do you interpret the lung volumes measured via body plethysmography, and how do they relate to those measured via helium dilution?

Table 3. Lung Volumes Obtained via Body Plethysmography

	Value (% of Predicted)
TLC (L)	3.97 (87)
TGV (L)	2.86 (142)
RV (L)	2.43 (252)
RV/TLC	0.61 (289)
ERV (L)	0.43 (41)
IC (L)	1.11 (43)
VC (L)	1.54 (46)

TLC = total lung capacity  
TGV = thoracic gas volume  
RV = residual volume  
ERV = expiratory reserve volume  
IC = inspiratory capacity  
VC = vital capacity

**Answer.** The lung volumes measured by body plethysmography show a normal TLC with an elevated thoracic gas volume and RV, consistent with hyperinflation. The inspiratory capacity, expiratory reserve capacity, and VC are similar to those obtained via helium dilution, suggesting similar degrees of effort, but the TLC, thoracic gas volume, and RV are all increased by approximately 1.7 L. This difference represents the volume of gas trapped within a noncommunicating region of the airway tree. Of the abnormalities described previously that could account for the diminished breath sounds, a space-occupying lesion such as a bronchogenic or pulmonary cyst would be most likely.

A chest radiograph (Fig. 2) revealed almost complete absence of lung markings on the left side, except for a few parenchymal markings seen in the extreme medial portion of the left apex. The heart and mediastinum were shifted to the right. The right lung appeared normal but compressed. A chest computed tomography (Fig. 3) confirmed the presence of a giant cyst occupying almost all of the left chest, with mediastinal shift to the right, compression of the right lung, and compression of a remnant of the left upper lobe and left lower lobe.

Because of concern that the cyst could lead to future pulmonary compromise by hindering normal enlargement of her healthy right lung and worsening pulmonary gas exchange in the already compressed left lung, the patient was referred for surgical resection. The patient underwent

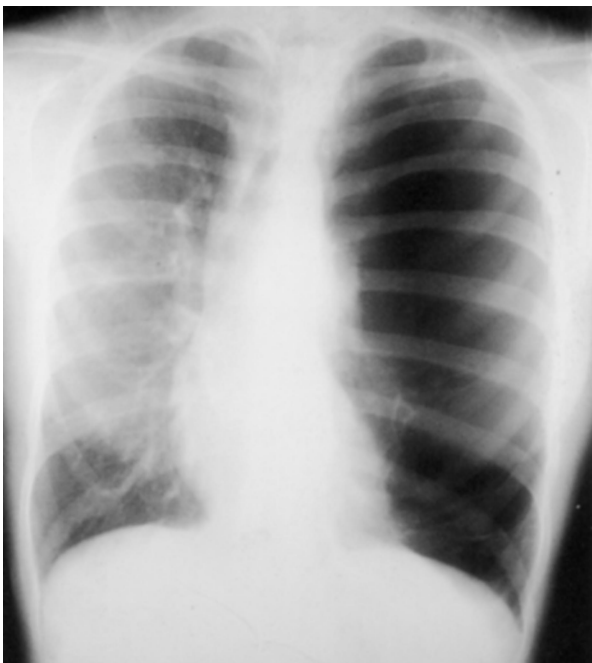

Fig. 2. Posterior-anterior chest radiograph revealing hyperlucency of the left lung, with only scant lung markings in the medial aspect of the left apex and hyperexpansion of the left hemithorax, with shift of the mediastinum to the right.

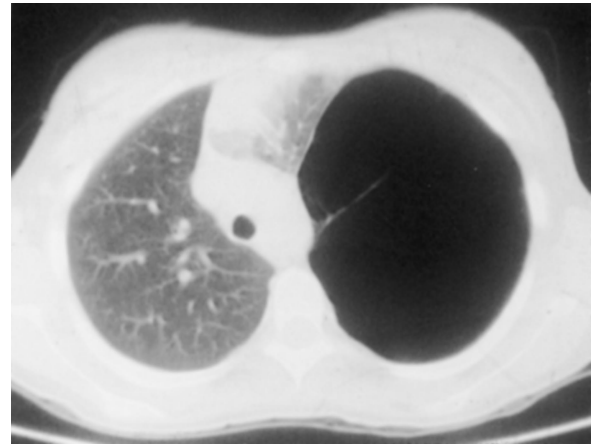


Fig. 3. Computed tomography scan of the chest at the mid-tracheal level, illustrating the large cystic lesion of the left thorax, with only a thin area of lung markings seen in the medial left apex, representing compressed left upper lobe.

an uncomplicated thoracotomy with excision of the cyst and removal of the lingula. The pathology specimen consisted of variably sized cysts lined by ciliated columnar epithelium and focal mucogenic columnar epithelium, compatible with the diagnosis of congenital cystic adenomatoid malformation of the lung, type I. The patient has remained asymptomatic, with slow re-inflation of the left upper and left lower lobe. Follow-up PFTs were obtained 1 year after surgery (Table 4 and Fig. 4).

**Question.** How do you interpret the spirometry and lung volumes in Table 4 and Figure 4?

**Answer.** The spirometry reveals a marked improvement in VC, with no evidence of air flow limitation. Lung volumes show no restriction, but there is hyperinflation. The equivalent results obtained with helium and plethysmography indicate the absence of substantial noncommunicating gas.

### Discussion

This case illustrates the relative advantages of measuring lung volumes via body plethysmography versus via gas dilution. Body plethysmography operates on the principle of Boyle's law<sup>2</sup> and therefore measures all compressible gas within the thorax, regardless of whether the gas is in direct communication with the airways. The gas dilution technique uses the principle of concentration-dilution<sup>3</sup> and therefore only measures those regions able to receive the inert gas, and so it is sensitive only to regions of communicating gas. Functionally the gas dilution technique is perhaps more appropriate than plethysmography, since oxygen will also distribute only to those areas that are in

## DIAGNOSIS OF A SPACE-OCCUPYING LESION OF THE LUNG BY PULMONARY FUNCTION TESTS

Table 4. Follow-up Spirometry and Lung Volumes 1 Year After Surgery

Spirometry	Value (% of Predicted)	
FVC (L)	2.81 (83)	
FEV <sub>1</sub> (L)	2.50 (83)	
FEV <sub>1</sub> /FVC	0.89 (101)	
Lung Volumes		
	Value (% of Predicted)	
	Via Helium Dilution	Via Body Plethysmography
TLC (L)	4.25 (83)	4.34 (85)
FRC (L)	2.59 (121)	2.67 (125)
RV (L)	1.50 (142)	1.58 (150)
RV/TLC	0.35 (155)	0.37 (161)

FVC = forced vital capacity  
 FEV<sub>1</sub> = forced expiratory volume in the first second  
 TLC = total lung capacity  
 FRC = functional residual capacity  
 RV = residual volume

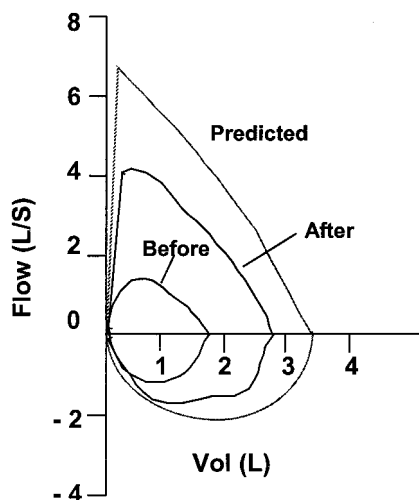


Fig. 4. Predicted flow-volume loop and loops obtained before and 1 year after surgery.

communication with the airways. In other words, the patient had a working TLC of only 50% of predicted, not the 87% of predicted seen via plethysmography. The gas dilution technique would have missed the fact that 1.7 L of gas was trapped in noncommunication with the rest of the airway tree. One clue that there was a region of noncommunicating gas during the helium dilution measurement was the relatively normal equilibration time. In diseases such as asthma and chronic obstructive pulmonary disease, in which there is some, albeit slow, communication through narrowed airways, equilibration time is prolonged or equil-

ibration is not achieved within the usual 10-min time limit of the test.

To best determine the presence of noncommunicating regions, measure lung volumes with both techniques and compare the results.<sup>4</sup> In this case the physical examination suggested a certain differential diagnosis that could be narrowed down with the knowledge that there was a large (1.7 L) region of noncommunicating gas.

It was important to remove the cystic malformation, because it was quite large and mechanically compromising regions of healthy lung, which could diminish pulmonary function by compressing adjacent healthy lung and increasing FRC. The increased FRC could contribute significantly to increased work of breathing.<sup>4</sup> Removal of large bullous lesions most consistently results in decreased FRC and improved oxygenation, which are related to re-expansion of healthy lung and reduced hyperinflation.<sup>4</sup> Indeed, after surgery FRC was reduced, in association with an impressive increase in FVC and FEV<sub>1</sub>. However, the patient still had substantially hyperinflated lungs, probably as a result of distention of the remaining lung parenchyma.<sup>5</sup> In young persons lung volume increases through adolescence,<sup>6</sup> so removing the space-occupying lesion was essential in order for our patient to realize her full lung-growth potential. In addition, most authors recommend surgical resection of such large lesions that are at risk of infection, rupture or, in the case of cystic adenoid malformations, the development of malignancy.<sup>7</sup>

In conclusion, this case illustrates the importance of understanding the physiology behind the technique of lung volume measurement, and how such an understanding can help lead to an anatomic diagnosis.

### REFERENCES

1. Kravitz RM. Congenital malformations of the lung. *Pediatr Clin North Am* 1994;41(3):453-472.
2. Dubois AB, Bothelo SY, Bedell GN, Marshal R, Comroe JH. A rapid plethysmographic method for measuring thoracic gas volume: a comparison with nitrogen washout method for measuring functional residual capacity in normal subjects. *J Clin Invest* 1956;35:322-326.
3. Meneely GR, Kaltrieder NL. Volume of lungs determined by helium dilution: description of method and comparison with other procedures. *J Clin Invest* 1949;28:129-139.
4. Pride NB, Barter CE, Hugh-Jones P. The ventilation of bullae and the effect of their removal on thoracic gas volumes and tests of over-all pulmonary function. *Am Rev Respir Dis* 1973;107(1):83-98.
5. Cagle PT, Thurlbeck WM. Postpneumectomy compensatory lung growth. *Am Rev Respir Dis* 1988;138(5):1314-1326.
6. Wang X, Dockery DW, Wypij D, Fay ME, Ferris BG Jr. Pulmonary function between 6 and 18 years of age. *Pediatric Pulmonol* 1993; 15(2):75-88.
7. Zach MS, Eber E. Adult outcome of congenital lower respiratory tract malformations. *Thorax* 2001;56(1):65-72.