

## Radiographically Occult Right Main Bronchus Intubation with a Fastrach Laryngeal Mask Airway Endotracheal Tube

Jon S Huseby MD and Steven Legault RRT

**We report a case in which the distal 3 cm of an LMA-Fastrach laryngeal mask airway (LMA) endotracheal tube (ETT) was radiographically invisible. After the LMA intubation, left lung atelectasis developed. The radiopaque wire coil built into the ETT was mistakenly believed to mark the end of the ETT, so the radiograph made it appear that the end of the ETT was 2 cm above the main carina. In fact, this type of ETT extends 3 cm beyond the end of the wire coil, and the final 3 cm of the ETT can be difficult or impossible to see on a radiograph. Bronchoscopy revealed that the end of the ETT was in the bronchus intermedius. In this case, even in retrospect, the true end of the ETT could not be seen on the radiograph. Clinicians should be aware that the final 3 cm of the LMA-Fastrach ETT can be radiographically invisible. We believe the manufacturer should redesign this ETT to include better radiopaque markers all the way to the end of the ETT.** *Key words: Fastrach, laryngeal mask airway, LMA, tracheal intubation, radiograph.* [Respir Care 2003;48(5):517–518. © 2003 Daedalus Enterprises]

### Introduction

Most endotracheal tubes (ETTs) have a radiopaque marker that allows for radiographic confirmation of the ETT's position. We report a case in which the distal 3 cm of the Fastrach laryngeal mask airway (LMA) (LMA North America, San Diego, California) ETT was radiographically invisible, which led to complications.

### Case Summary

A 152 cm, 45 kg, 26-year-old woman developed severe vaginal bleeding following an emergency cesarean section. Because of respiratory distress and hemodynamic instability tracheal intubation was required. Initial attempts at intubation (laryngoscopic and fiberoptic bronchoscopic) were unsuccessful, but eventually the patient was intubated with the LMA-Fastrach system.<sup>1</sup> A #8 ETT was

used and secured at the 24 cm mark. At that time breath sounds were thought to be clear and equal. The patient was immediately taken to surgery, where a hysterectomy was performed for uterine atony. Because of continued hemodynamic instability she was brought to the intensive care unit, intubated, and ventilator support was maintained. The patient was given a tidal volume of 450 mL, which resulted in a peak inspiratory pressure of 25 cm H<sub>2</sub>O. With a 0.50 fraction of inspired oxygen her pulse-oximetry-measured oxygenation was 94%. A chest radiograph (Fig. 1) showed almost complete atelectasis of the left lung. However, the radiopaque wire coil in the ETT, which appeared to represent the end of the ETT, ended 2 cm above the main carina. The patient's history suggested a recent pneumonia and, earlier in life, tuberculosis. Bronchoscopy revealed that the end of the ETT was in the bronchus intermedius. The ETT was pulled back 4 cm, where direct observation showed it to be in good position. A repeat chest radiograph (Fig. 2) showed the wire coil to end at the clavicular level. Twenty-four hours later the atelectasis had resolved and the patient was successfully extubated.

### Discussion

The LMA-Fastrach is an airway management device that can be used for airway control, ventilation, oxygenation without intubation, and for endotracheal intubation,

Jon S Huseby MD and Steven Legault RRT are affiliated with the Section of Pulmonary and Critical Care, Swedish Medical Center, Providence Campus, and the Department of Medicine, University of Washington, Seattle, Washington.

Correspondence: Jon S Huseby MD, Section of Pulmonary and Critical Care, Swedish Medical Center, Providence Campus, 1145 Broadway, Seattle WA 98122.

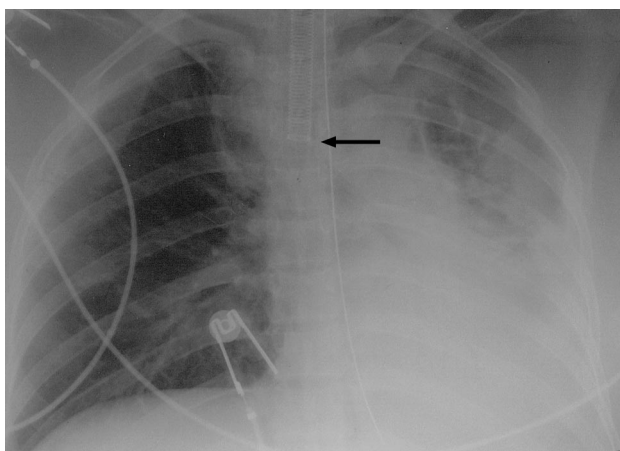


Fig. 1. Radiograph showing atelectasis of the left lung. The wire coil in the endotracheal tube (ETT, arrow) ends above the main carina, but the end of the ETT is 3 cm beyond the end of the wire coil.

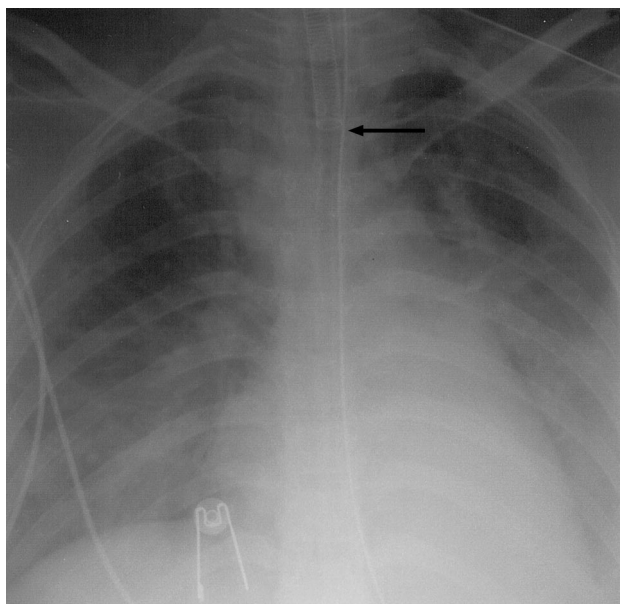


Fig. 2. Radiograph after repositioning endotracheal tube (ETT). The wire coil in the ETT (arrow) ends at the clavicular level so that the end of the ETT is 2 cm above the main carina. Atelectasis is resolving.

by blindly passing an ETT through the LMA. On direct examination of the LMA-Fastrach ETT (Fig. 3), the problem became apparent. The wire coil, which gives the ETT flexibility while preventing collapse, ends 3 cm from the distal end of the ETT. The 3 cm tip is made of silicone rubber, and though it has radiopaque markers on both sides, all the way to the end of the tube, these are easily missed on chest radiograph. In other ETTs of the same

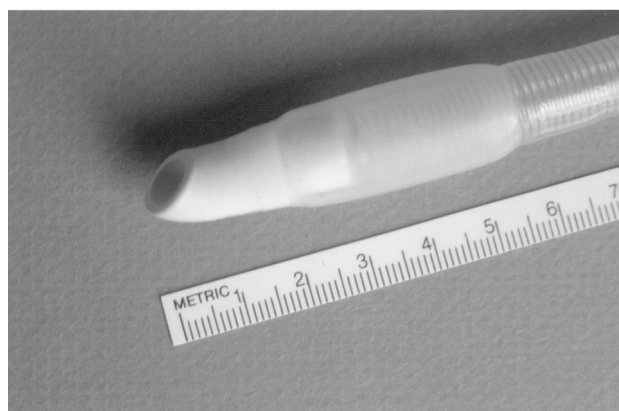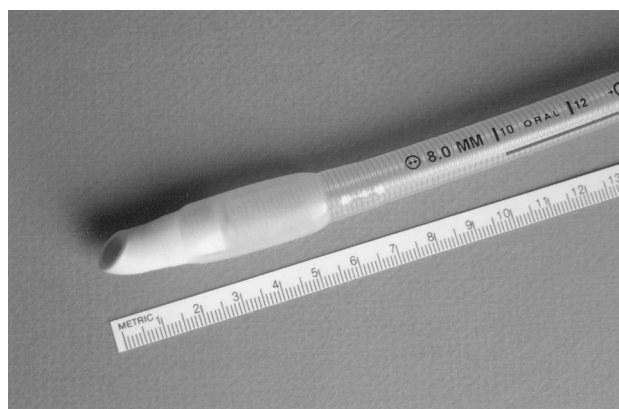


Fig. 3. LMA-Fastrach laryngeal mask airway endotracheal tube. Note that the wire coil built into the tube ends 3 cm before the end of the tube.

basic design (eg, Rüsch) the wire extends much closer to the end of the ETT. This problem has been previously reported in the case of a patient intubated with a #7 Mallinckrodt ETT,<sup>2</sup> so this may be a generic problem with several armored tubes.

Undoubtedly our patient's small size increased the possibility of bronchus intermedius intubation. When the ETT was in good position, 2 cm above the main carina by direct observation, the radiograph showed the wire coil ending at about the clavicular level. Anesthesiologists, emergency department personnel, critical care physicians, and respiratory therapists should be aware of this potential complication; we believe the manufacturer should redesign this ETT to include a better radiopaque marker all the way to the end of the ETT.

#### REFERENCES

1. Parr MJA, Gregory M, Baskett PFJ. The intubating laryngeal mask: use in failed and difficult intubation. *Anesthesia* 1998;53(4):343-348.
2. Gorbach MS, Ravin CE. Reinforced endotracheal tube placement: radiographic misdiagnosis. *Radiology* 1987;162(2):579.